

Benign Solid Thyroid Nodules: US-guided High-Intensity Focused Ultrasound Ablation — Initial Clinical Outcomes

R. D. Kovatcheva, J. D. Vlahov, J. I. Stoinov, K. Zaletel; Radiology; 2015

Rationale

The prevalence of thyroid nodules found by means of palpation is approximately 5%, but an estimated 50% of unselected populations have nodules that can be discovered at ultrasonography. 95% of all thyroid nodules are benign.

Even if surgery is the treatment of choice, risks of complications lead to the development of various non-surgical, minimally invasive techniques.

Methods

20 euthyroid patients diagnosed with a benign solitary or dominant thyroid nodule were treated in one session with ultrasound-guided high intensity focused ultrasound (i.e. echotherapy)

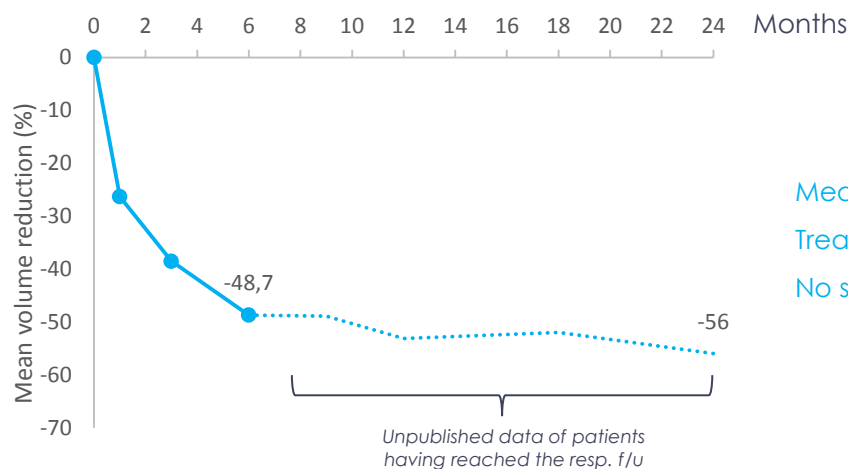
Mean thyroid volume at baseline: 4.96 ml ± 2.79

Mean patient age: 44.5y [24-65]

Treatment on an outpatient basis and under conscious sedation

Results

Mean volume reduction over time (% vs. months)



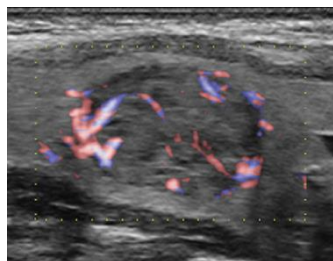
Mean procedure duration: 86.8min [37-152]

Treatment well tolerated by all the patients

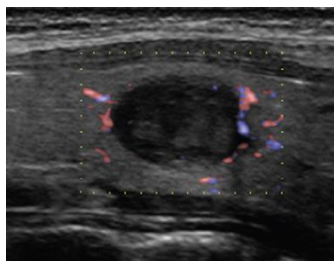
No serious adverse event

Color Doppler US images of longitudinal scan in a 42yo woman

Before echotherapy

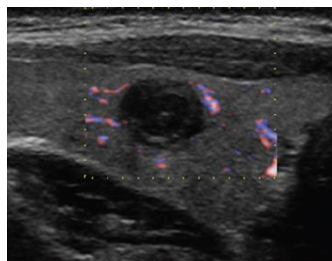


1 month after



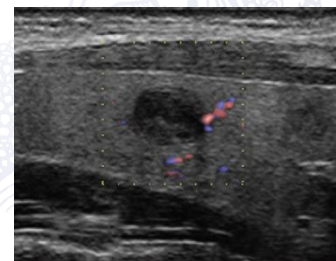
65.3% volume reduction

3 months after



86.5% volume reduction

6 months after



92.9% volume reduction

Conclusion

Echotherapy is an effective and safe non-invasive treatment method for benign solid thyroid nodules.